

Just Inject the Occlusion-Bearing Posterior Tooth Restorations with Beautifil Flow Plus

Dentist Uwe Diedrichs unveils an addition to the SHOFU range of products and indications from the new Beautifil Flow Plus

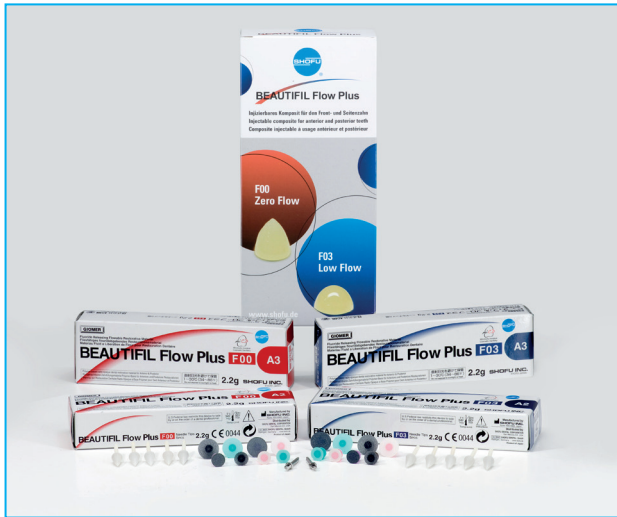

Figure 1

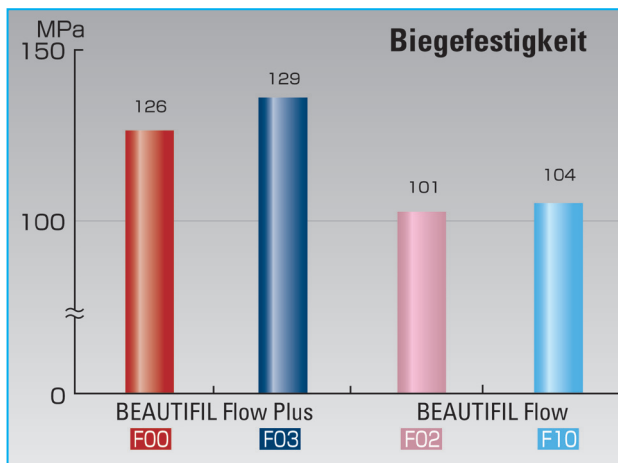


Figure 2

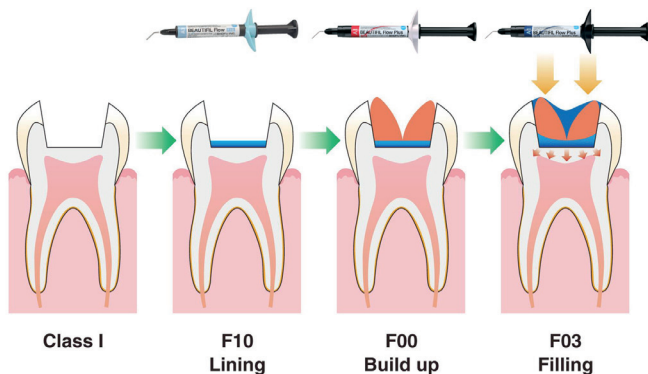


Figure 3

The hallmark of the Beautifil II restoration system, a submicrometer hybrid composite from SHOFU Dental in Ratingen, Germany, is its light conducting and light scattering properties that are analogous to enamel and dentin, its extraordinary formability and the capability of the patented S-PRG (Surface Pre-reacted Glass) filler technology to absorb and emit fluoride. Added to this is the thin-flowing (F10) and viscous (F02) Beautifil Flow with a colour that is perfectly matched to Beautifil II. It even includes all of the benefits of the Giomer product category. This means that it is perfect for the needs of all of the classical indications for flow composites in the system including the flow-matrix technique or flowable frame technique. One innovation is extending the indication for flowables to the occlusion-bearing posterior tooth zone that SHOFU encompasses with its Beautifil Flow Plus product line.

The idea behind Beautifil Flow Plus is achieving the highest mechanical characteristics while retaining the easy handling typical for flow materials. Beautifil Flow Plus is now available in an injectable (although completely stable) F00 option and a moderately flowable F03 option (Figure 1). Both of them can be used in the well-known flow indications as well as the filling therapy in the anterior and posterior tooth zone. What is absolutely new is the

fact that these flow materials are approved both for class I and class II occlusion-bearing restorations. They have an offset yield stress of more than 50% higher than the classical Beautifil Flow (F00: 121 MPa, F03: 115 MPa), flexural strength almost 30% higher (Figure 2) and a modulus of elasticity of 8.5 (F00) or 8.4 GPa (F03). They are what provide the physical foundations for extending the indication. A highly reinforced plastic matrix and large proportion of filler with a special particle structure are responsible for this in terms of material development.

Both levels of viscosity are available in the colours A1, A2, A3, A3.5, A4, A0.5 and the more opaque A20 including the incisal enamel colour (Inc) and a bleaching white (BW). In addition, there are the A0.50 and A10 opaque colours, the A30 opaque, a milky (MI) and cervical (CV) in F00. As with all of the Beautifil Flows, the Flow Plus composites can be easily applied directly from syringes thanks to a replaceable fine cannula and a finger-grip that can be rotated 360 degrees.

The Cone Technique

The cone technique is a layering technique that comes from the availability of directly injectable and absolutely stable flow materials. Conical increments are injected into the central cavity as if you wanted to premodel structures supporting cusps or cusp edges.

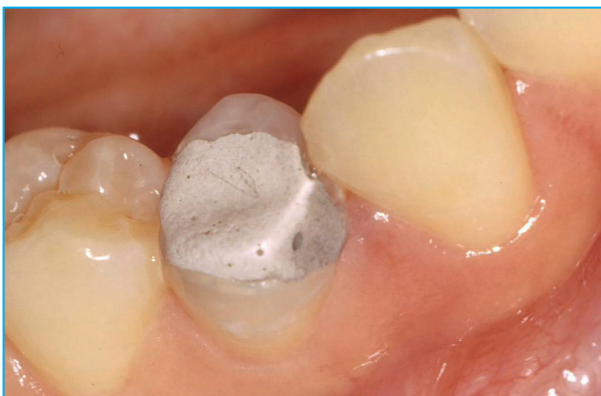

Figure 4

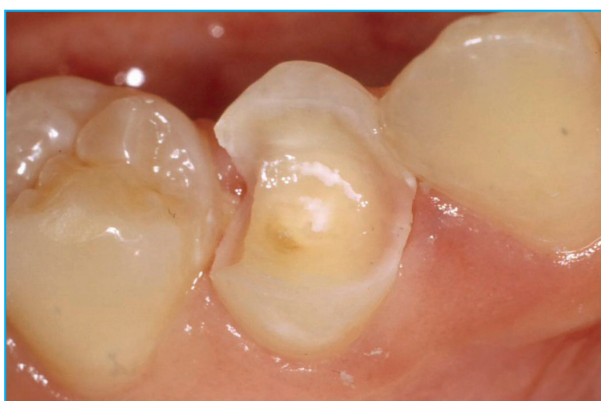

Figure 5

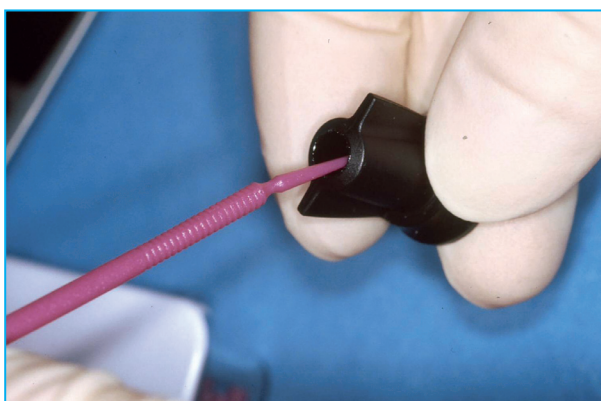


Figure 6

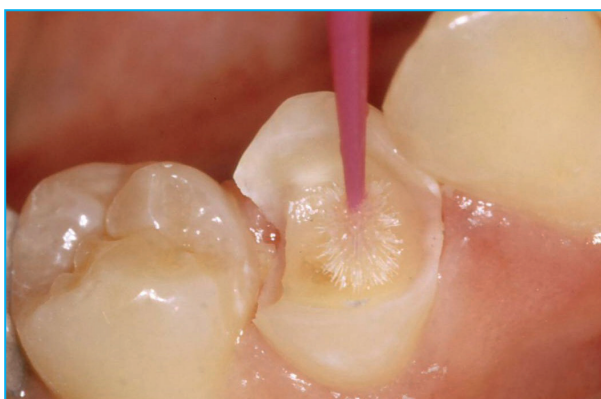

Figure 7

These cones are light-polymerised in one step without running by then. This process directly applies and polymerises virtually all important structures of the restoration in one step without exposing the bonding layer to critical tension. It is best to keep low the ratio of bonded to free surfaces (and therefore the C-factor) because even though a considerable volume of composites is brought in, there are mostly free surfaces due to individual structures conically narrowing to the occlusal. Finally, the restoration is completed (possibly in component steps) with a less stable flow material (Figure 3) and there is also the option bringing in a classical flow such as a liner on the cavity floor.

Patient Case

We will now use the example of the case of a patient to demonstrate the practical procedure with the cone technique using BeautiBond and Beautifil Flow Plus. The original situation was that tooth 44 had a long-term provisional restoration that was set in an emergency after the buccal cusp was fractured and the filling was lost (Figure 4). After removing the gray glass ionomer filling, the cavity was prepared for taking the composite restoration and the enamel was slightly bevelled (Figure 5). The decision was made to proceed with the cone technique with a modified application of a partial matrix system due to the extended position of the fault which meant that it was obvious that buccal and approximal contouring would be difficult. A seventh generation single-component adhesive was used while drying it out relatively (Figure 6 and 7). One of the qualities of BeautiBond

is the fact that it has a very thin bonding film resistant to hydrolysis and it has almost comparable bonding strength as the two-component adhesives. Furthermore, the special composition of BeautiBond rules out white discolouration of the gingiva thus minimising the risk of post-operative sensitivity. This means that it only requires a single component applied once very quickly to provide the foundation for highly aesthetic restorations.

The next thing is laying out the approximal walls of the restoration. The combination of easy injectability and absolute stability also predetermines Beautifil Flow Plus F00 for this job (Figure 8 and 9). With conventionally plugged composites in this step, there is always the danger that the portion rises basally in the approximal box by sticking to the application instrument. This causes a lack of sealing on the edge, air occlusions or „material faults“ when layering up against the matrix. The result is a non-homogeneous filling surface in the approximal restoration zone that cannot be accessed later. For all practical purposes, these risks are ruled out if a flow is used that is approved for this indication.

The occlusal and buccal restoration components are built up with the cone technique taking advantage of all of the benefits already mentioned in this article. The cones supporting the cusp are built up directly and light-polymerised from the application injection with the factual no flow F00 (Figure 10). The result of this step is always somewhat reminiscent of the Tuffstein landscapes in Capadocia in Turkey and forms the basis for the complementary application with Beautifil

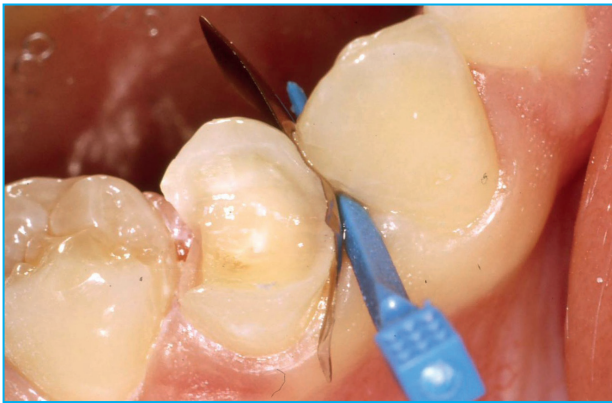

Figure 8

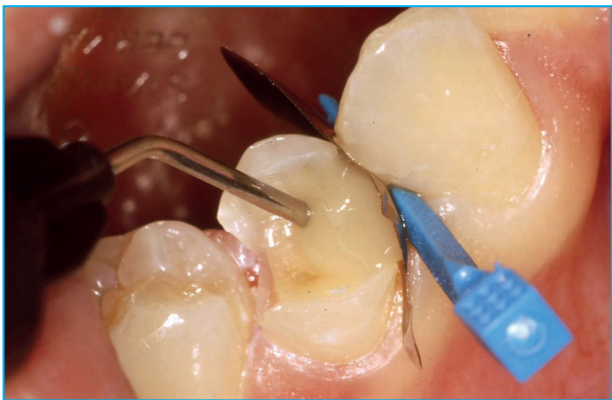

Figure 9

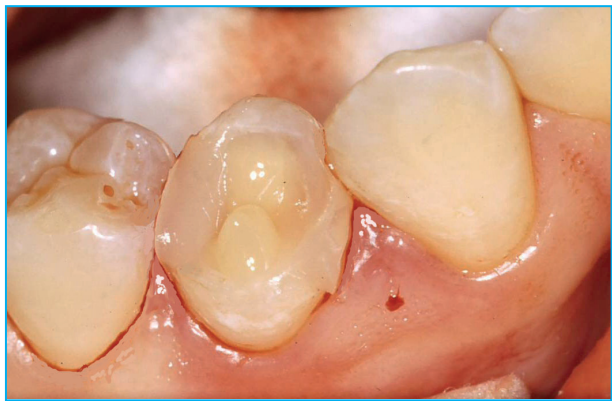

Figure 10

Flow Plus F03. The contrast shown by Figure 11 illustrates very clearly the different viscosities of the two Beautifil Flow Plus options: the conical portion of Beautifil Flow Plus F00 (on the left-hand side) is absolutely stable directly after application and after minute while in comparison option F03 (on the right-hand side) is moderately flowable.

Beautifil restoration system is a unique advantage for the user. The aesthetic qualities typical of Beautifil can be combined with the most agreeable handling properties and economical work strategies in all indications zones.

**Uwe Diedrichs,
Neuss and Vaduz**

After completing the restoration with Beautifil Flow Plus F03 and subsequent light polymerisation, it is worked on with grit finishers and polished with the polishers of the CompoMaster system (Figure 12) or polished to a high gloss. Figure 13 shows the final results of the occlusion-bearing posterior restoration of tooth 44 that was completely injected with flow materials directly after completion. Adding Flow Plus products to the

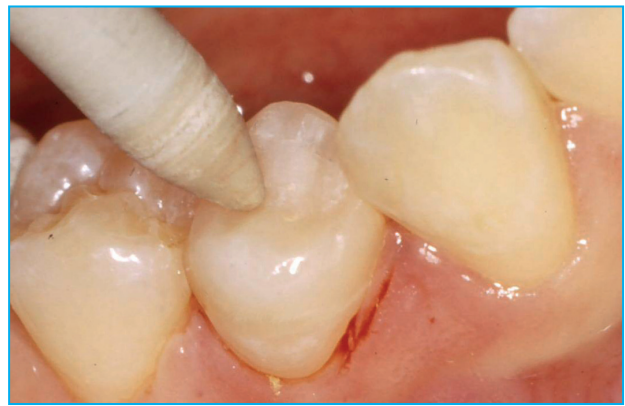

Figure 12

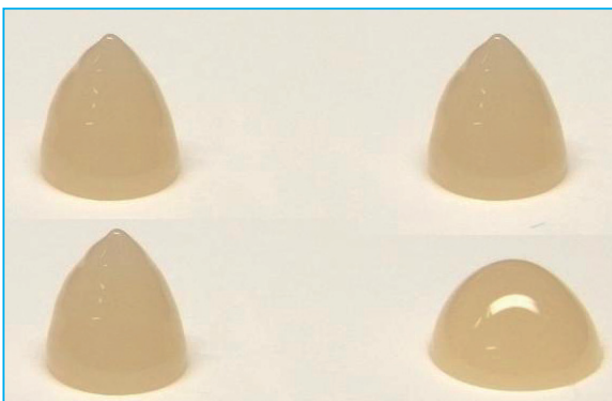

Figure 11

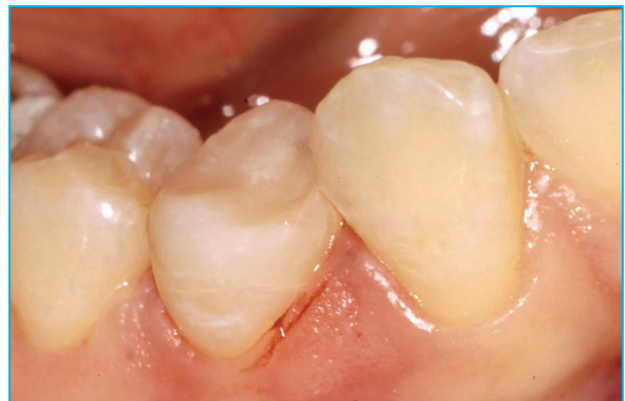

Figure 13

Captions

- Figure 1:** Beautifil Flow Plus with the F00 and F03 flowability in the handy 2-gram syringes with a rotating finger grip
- Figure 2:** The flexural strength [MPa] of Beautifil Flow Plus F00 and F03 in comparison to the classical Beautifil Flow F02 and F10
- Figure 3:** An example of a layering scheme for the cone technique with the F10 lining on the cavity floor, cone-shaped cusp model-
lation with the stable F00 and finally completing with F03
- Figure 4:** The initial situation with the MOD defect and loss of the buccal cusp in 44 that had a long-term temporary repair using
glass ionomer cement
- Figure 5:** The cavity prepared for accepting the directly injected restoration with Beautifil Flow Plus using an enamel and dentin
adhesive
- Figure 6:** Removing the BeautiBond single-component adhesive from the unit dose
- Figure 7:** BeautiBond is applied with an effective time of 10 seconds, 3 seconds carefully and then blown on at a high level of air
pressure and light-polymerised
- Figure 8:** A modified incremental matrix system was installed for mesial approximal contouring
- Figure 9:** The Beautifil Flow Plus flow composite is injected in the extremely stable F00 option for building up the mesial filling
component against the matrix wall
- Figure 10:** The distal filling component and cone-shaped cusp modellation is formed with Beautifil Flow Plus F00 in the same fashion
with a direct injection
- Figure 11:** The extraordinary stability of Beautifil Flow Plus F00 (on the left hand side) in comparison to the moderate flowability of
the F03 option (on the right-hand side) shows a comparison of the cone-shaped modellation directly after injection (on top)
with the results after one minute of standing (below).
- Figure 12:** It is precision-worked after completing the restoration with the moderately flowable Beautifil Flow Plus F03 and it is given
polishing with the CompoMaster system from SHOFU.
- Figure 13:** The directly injected occlusion-bearing modv flow composite-restoration on tooth 44 directly after completion

First published in „DZW Die ZahnarztWoche“ Ausgabe 44/10 from 03. November 2010.